

The Hepatoprotective Effect of Bael Leaves (*Aegle Marmelos*) in Alcohol Induced Liver Injury in Albino Rats

Vinodhini SINGANAN¹, Malairajan SINGANAN² and Hazeena BEGUM³

¹Dept. of Applied Biology, Ambo College – Jimma University, P.O.Box. 19, Ambo Town, Western Shoa, ETHIOPIA

²Dept. of Applied Chemistry, Ambo College – Jimma University, P.O.Box. 19, Ambo Town, Western Shoa, ETHIOPIA

³Unit of Biochemistry, Dept. of Siddha Medicines, Fac. of Sci., Tamil University, Thanjavur – 613 007, Tamil Nadu, INDIA
swethasivani@yahoo.co.in

(Received: 02.01.2007; Accepted: 19.03.2007)

Abstract: Herbal drugs are traditionally used in various parts of the world to cure different diseases. The Ayurvedic and Siddha medical systems are very famous medical practices in Indian traditional medicines. In the present research studies, Bael leaves (*Aegle marmelos*, family of *Rutaceae*) which are also called as Bilva in ancient Sanskrit was used as herbal drug and its hepatoprotective effect in alcohol induced liver injury in albino rat was evaluated using essential biochemical parameters. The experiments were performed with four groups of animals. The experimental animals were administered with 30% ethyl alcohol for a period of 40 days and the fine crude plant leaves powder was fed to animals for next 21 days. The observed values of TBARS (Thiobarbituric acid reactive substances) in healthy, alcohol intoxicated and herbal drug treated animals were 123.35, 235.68 and 141.85 µg/g tissue respectively. The results were compared with the standard herbal drug silymarin (133.04 µg/g tissue). The experimental results indicate that, the Bael leaves have excellent hepatoprotective effect. A similar experimental result was also observed in other biochemical parameters.

Keywords: Herbal drugs, Bael leaves, Alcohol toxicity, Liver injury and Albino rats.

Albino Ratlarda Alkolün Sebep Olduğu Karaciğer Yaralarında Bael Yapraklarının (*Aegle Marmelas*) Hepatoprotektif Etkisi

Özet: Bitkisel ilaçlar dünyanın çeşitli yerlerinde bir takım hastalıkların tedavisinde geleneksel olarak kullanılmaktadır. Hyurvedik ve Siddha medikal sistemleri Hint geleneksel tıbbının çok ünlü tıbbi uygulamalarıdır. Günümüzün araştırma çalışmalarında antik Sanskritte Bilva olarak adlandırılan Bael yapraklarının (*Aegle Mammelas*, *Rutaceae* ailesi) bitkisel bir ilaç olarak kullanımını ve albinoratlarda alkolün sebep olduğu karaciğer yaralarındaki hepatoprotektif etsinin gerçek biyokimyasal parametreler kullanarak hesaplanması incelenmektedir. Deneyler dört grup hayvan üzerinde yapılmaktadır. Deney hayvanlarına 49 günlük periyotlarla % 30 etil alkol verilmektedir ve sonraki 21 günde de hayvanlar ham bitki yaprakları tozu ile beslenmektedir. Sağlıklı durumda, alkol verilmiş ve bitkisel ilaçlarla tedavi edilmiş hayvanlarda TBARS (Thiobarbituriliasit reauif maddeleri)'in gözlenen değerleri sırasıyla 123-35, 235-68 ve 141-85 Mg/g şeklinde bulunmuştur. Sonuçlar standart bitkisel ilaç silymarin (133.04 Mg-g dow) ile karşılaştırılmıştır. Deney sonuçları, Bael yapraklarının hepatoprotektif etkininin mükemmel olduğunu göstermektedir. Diğer biyokimyasal parametrelerle de benzer deney sonuçları gözlenmektedir.

Anahtar Kelimeler: Bitkisel ilaçlar, Bael yaprakları, Karaciğer yarası ve Albinoratlarda.

Introduction

Indigenous plants have been the traditional source of raw materials for the manufacture of medicines. The diverse culture of our country is a rich source of traditional medicines, many of which one of plant origin scientific data on such

plant derivatives could be of clinical importance (Gupta, 1994). The trend of using natural products has increased and the active plant extracts are frequently screened for new drug discoveries (Das et al., 1999).

Aegle marmelos, commonly known as Bael, is a spiny tree belonging to the family Rutaceae. It is an indigenous tree found in India, Myanmar, Pakistan and Bangladesh. The leaves, roots, bark, seeds and fruits are edible and medicinal values. The medicinal properties of this plant have been described in the Ayurveda. In fact, as per Charaka (1500 B.C) no drug has been longer or better known or appreciated by the inhabitants of India than the *Bael*.

The leaves of *Bael* are astringent, a laxative, and an expectorant and are useful in treatment of ophthalmia, deafness, inflammations, cataract, diabetes, diarrhoea, dysentery, heart palpitation, and asthmatic complications (Kirtikar and Basu, 1993). It has been claimed the leaf of *Aegle marmelos* possess contraceptive efficacy (Bhattacharyay, 1982). Fresh aqueous and alcoholic leaf extracts of *Aegle marmelos* were reported to have a cardio tonic effects in mammals (Haravey, 1968 and Nadkarni, 2000).

Aegle marmelos leaf extract has been reported to regenerate damaged pancreatic beta cells in diabetic rats (Das et al., 1996) and increased the activities of peroxidase in the liver tissues of Isoproterenol treated rats (Rajadurai et al., 2005). An aqueous decoction of the leaves has been shown to possess a significant hypoglycemic effect (Karunanayake et al., 1984).

Aegle marmelos leaf extract was found to be a potential antioxidant drug, which reduces the blood sugar level in alloxan induced diabetic rats (Sabu and Ramadasan, 2004). It was found to be as effective as insulin in the restoration of blood glucose and body weight to normal levels on hyperglycemic state (Seema et al., 1996).

The ethanolic extract of *Aegle marmelos* leaf possesses anti spermatogenic activity (Sur et al., 1999) and aqueous extract of the leaf has anti motility action on spermatozoa in rats (Sur et al., 2002). Considering the diverse medicinal properties of *Aegle marmelos*, the present study was under taken to evaluate the hepatoprotective effect of *Aegle marmelos* in alcohol induced liver injury in experimental animal models.

Materials and Methods

Plant Material

Leaves of *Aegle marmelos* were collected from Thanjavur district of Tamil Nadu, India during the months of September – December. Fresh leaves were dried at 45°C for 48 hours, powdered using electric grinder, and stored in a desiccator. This fine crude powder was used as herbal drug.

Selection of Animals

In this experiments twenty four healthy male albino Wistar strains rats, 3 months of age, weighing 150 – 190g were selected for acclimation for a period of two weeks in laboratory animal house and maintained under standard conditions of temperature $27 \pm 2^{\circ}\text{C}$, relative humidity of $60 \pm 5\%$ and 12: 12 hour light: dark cycle prior to experimentation. The animals were fed with standard pellet diet and water ad libitum. The experimental animals were divided into four groups (G1, G2, G3 and G4) each contains six animals as per the drug treatment plan. First group served as control and the rest served as experimental groups. The ethics committee of Tamil University, Thanjavur, approved the protocol of the present study.

Drug treatment protocol

The fine powder of *Aegle marmelos* leaves were suspended in physiological saline and administered to the experimental animals intragastrically as per the following experimental protocol. The first group (Control) received small amount of physiological saline and the animals has free access to standard feed and water for 40 days. The second group was intoxicated with 1mL of 30% ethyl alcohol once in a day in afternoon for 40 days. The third group was intoxicated with 1mL of 30% ethyl alcohol similarly as second group. Further, the animals were treated with the powder of *Aegle marmelos* herbal drug (1g / Kg. b. wt) twice a day (morning and evening) for 21 days. The fourth group served as reference animals, which were intoxicated similarly as third group

and treated with the standard drug silymarin at a dose (0.1g / Kg. b. wt) twice a day for 21 days.

Biochemical Assays

At the end of the drug treatment period, all the animals were anaesthetized by application of light chloroform and blood samples were collected from a group of animals from dorsal aorta by heparinized syringe in vacutainer tubes. Plasma was separated from the collected blood by centrifugation at 3000 g for 5 minutes. Separate blood samples were collected from another group

of anaesthetized animals in glass test tubes and allowed to coagulate for 30 min. Serum was separated by centrifugation at 3000 g for 20 minutes. Plasma and serum samples were kept at – 20°C for biochemical analysis.

The animals were sacrificed by cervical decapitation, the perfused liver of each animal was dissected out and washed with isotonic solution, and their wet weight was recorded. The liver homogenate was prepared using phosphate buffer solution for biochemical analysis. The biochemical parameters analyzed from serum, plasma and liver homogenate was presented in the Table 1.

Table 1. Biochemical parameters analyzed in liver homogenate, plasma and serum.

Biochemical parameters	References
Thiobarbituric acid reactive substances (TBARS)	Ohkawa et al., 1979; Esterbauer and Cheeseman, 1990
Reduced glutathione (GSH)	Sedlak and Lindsay, 1968
Superoxide dismutase (SOD)	Sun et al., 1998; Kakkar et al., 1984
Glutathione peroxidase (GPx)	Paglia and Valentine, 1967
Catalase (CAT)	Beers and Sizer, 1952
Vitamin – E	Barker et al., 1980
Plasma Ascorbic acid (Vitamin – C)	Besada, 1987; Noroozifar and Khorasani – Motlagh, 2003
Iron (Serum)	Yee and Goodwin, 1974
Copper (Serum)	Yee and Goodwin, 1974

Results and Discussions

Thiobarbituric acid reactive substances (TBARS)

The thiobarbituric acid assay is the most popular method of estimation of malondialdehyde level, which is an indication of lipid peroxidation and free radical activity. The increase in lipid peroxidation, a degradative process of membrane polyunsaturated fatty acid has been suggested by the increase in malondialdehyde in ethanol induced toxicity in the liver. The increased lipid peroxidation results in changes in cellular metabolism of the hepatic and extra hepatic tissues, which ultimately leads to the whole cell deformity and cell death (Winrow et al., 1993).

The levels of TBARS in liver tissues of ethanol intoxicated rats were significantly elevated when compared to the level of TBARS in control animals. The administration of herbal drugs *Aegle marmelos* at the therapeutic doses (1g/Kg. b.wt) showed maximum reduction in TBARS level. The standard hepatoprotective drug Silymarin maintained the decreased lipid peroxidation level to the normal limits in the liver. The results indicate that, the herbal drug *Aegle marmelos* has very good hepatoprotective effect in liver damage. The results were presented in the Figure 1.

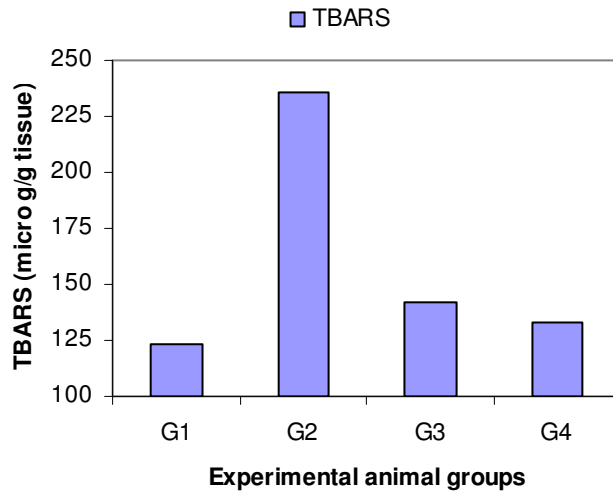


Fig 1. Effect of *Aegle marmelos* in TBARS level.

Glutathione Reductase (GSH)

It is an important source of reducing equivalents during oxidative stress generated by reactive oxygen species. The higher level of ethanol intake develops cirrhosis and liver damage by enhancing lipid peroxidation in the liver. Acetaldehyde the toxic metabolite of ethanol depresses the liver and plasma glutathione level by conjugating with the sulphhydryl groups of glutathione (Comporti et al., 1973). In the present research work, we have observed the decreased level of glutathione in ethanol intoxicated rats.

The GSH depletion in hepatic mitochondria is considered the most important sensitizing mechanism in the pathogenesis of alcoholic liver injury. Treatment with *Aegle marmelos* herbal drug had significantly improved the level of glutathione both in plasma and lever tissues. Similar results also observed with the standard drug Silymarin. The results were presented in the Figure 2.

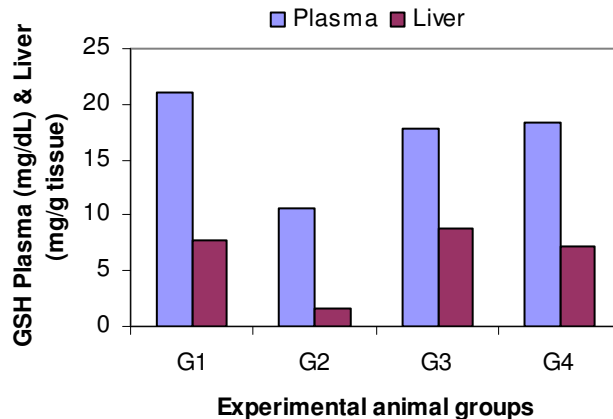


Fig 2. Effect of *Aegle marmelos* in GSH level in plasma and liver.

Superoxide dismutase (SOD)

SOD is the major attractive metalloprotein in the antioxidant family. The increased synthesis of superoxide dismutase against superoxide anion radical ($O_2^{\cdot -}$) production is an adaptive response of the cell to synthesis increased mitochondrial SOD through the stimulation of gene transcription (Das et al., 1997). The enzyme SOD was found to be decreased in ethanol intoxicated rats. This is due to the low level of Zinc (a metal constituent of the enzyme SOD) in plasma and liver tissues (Reding

et al., 1984). The low level of zinc was also found in alcoholic liver cirrhosis (Henkin and Smith, 1972).

In the present study, significant decrease in the activity of liver SOD in ethanol intoxicated rat was observed. The therapeutic treatment with *Aegle marmelos* herbal drug significantly improved the level of SOD in liver. This result indicates that, the herbal drug promoted the hepatoprotection by elevating free radical scavenging activity. Similar results were also observed in Silymarin treated rats. The results were presented in the Figure 3.

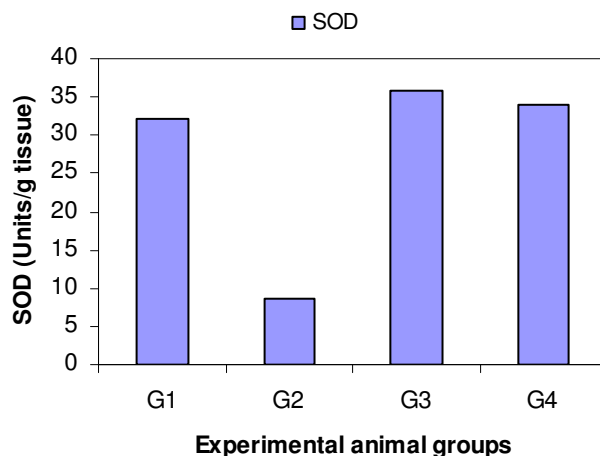


Fig 3. Effect of *Aegle marmelos* in SOD level.

Catalase (CAT)

The defensive antioxidant enzyme next to SOD is catalase. CAT traps the harmful hydrogen peroxide and converts into water and oxygen. The activity of catalase was found to be decreased in ethanol intoxicated rats. The inhibition of catalase activity during ethanol induced toxicity may be due to the increased generation of reactive free radicals, which can create an oxidative stress in the cells.

The administration of herbal drug *Aegle marmelos* inversed the catalase activity in the liver tissues and protected from the free radical induced oxidative stress (Rajashree et al., 1998). This results supports that, the antioxidant properties of the herbal drug was excellent as compared with the standard drug Silymarin. The results were presented in the Figure 4.

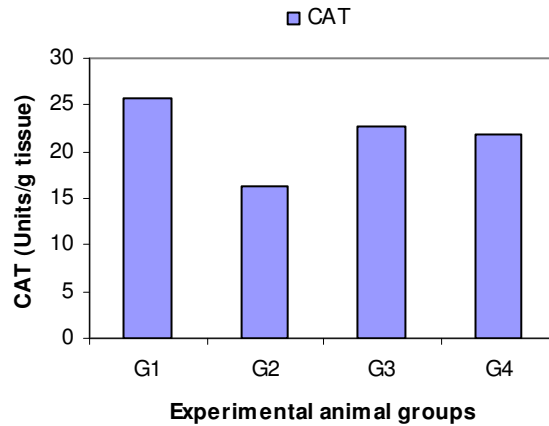


Fig 4. Effect of Aegle marmelos in CAT level.

Glutathione peroxidase (GPx)

GPx is a selenium dependent enzyme has high potency in scavenging reactive free radicals. In the present experiments, the levels of glutathione peroxidase activity in liver was elevated during alcohol intoxication to compensate the free radical scavenging effect utilized by the GSH as the

substrate (Rajashree et al., 1998). When GPx activity in liver increased, the glutathione level is decreased in ethanol fed rats. Treatment with the herbal drug *Aegle marmelos* significantly decreased the level GPx to normal level. The standard drug Silymarin showed equivalent effect in the GPx level in the ethanol intoxicated rats. The results were presented in the Figure 5.

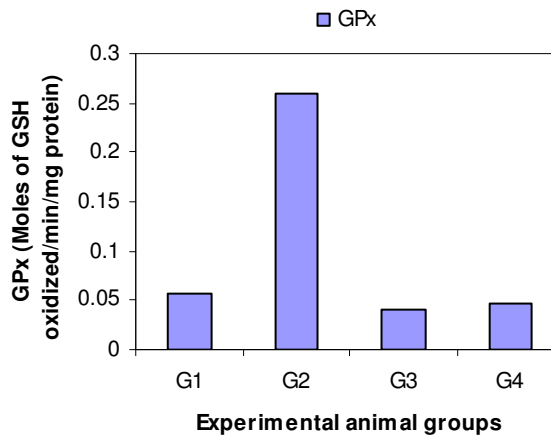


Fig 5. Effect of Aegle marmelos in GPx level.

Vitamin E and C

Vitamin E and C are natural antioxidants found in variety of plant materials. Ascorbic acid is most

powerful antioxidant under physiological conditions. It exists mostly in the reduced form. It

can directly scavenge superoxide, hydroxyl radicals and single oxygen. The ascorbic acid reduces H_2O_2 to water via ascorbate peroxidase reaction (Noctor and Foyer, 1998).

Vitamin – E is a chain breaking antioxidant. It can repair oxidizing radicals directly, and preventing the chain propagation step during lipid autoxidation (Serbinova and Packer, 1994). In our present research work, the decreased level of these vitamins was observed in ethanol intoxicated rats. This may be due to the high level of oxidative stress during the intoxication. The reduced form of glutathione substrate (GSH) is

required for the regeneration of vitamin C, which is intern necessary for the regeneration of vitamin E (Thomas et al., 1992). The ascorbic acid functions as an aqueous phase antioxidant.

Therapeutic treatment with the herbal drug *Aegle marmelos* in intoxicated rats significantly increased level of vitamin E and C through the influence of GSH regeneration. Thus, the herbal drugs exert a beneficial effect in regenerating the GSH through the recycling mechanism of these vitamins. The standard drug Silymarin has similar effect in GSH regeneration. The results were presented in Figures 6 and 7.

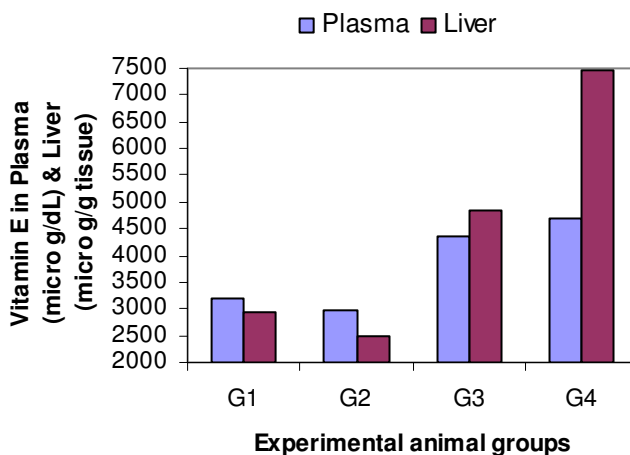


Fig 6. Effect of *Aegle marmelos* in vitamin E in plasma and liver.

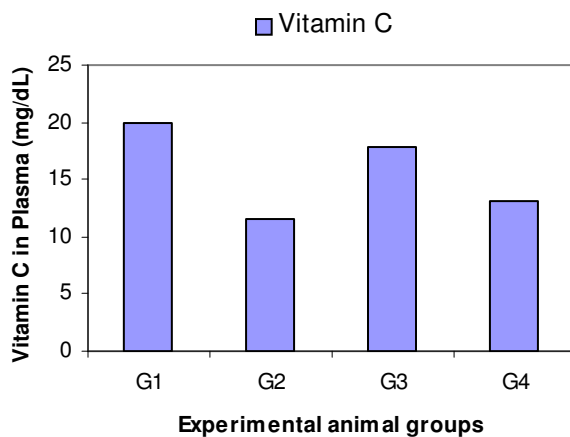


Fig 7. Effect of *Aegle marmelos* in vitamin C level in plasma

Iron and Copper

Serum iron and copper levels were significantly increased in ethanol intoxicated rats, when compared with the control animals. The increased serum iron level indicates that, the generation of toxic hydroxyl radicals. In the present study, we have observed that, the herbal drug treatment with *Aegle marmelos* drastically decreased the unbound serum iron. It may be through the chelating properties of flavonoids compounds of the herbal drug. *Tinospora cordifolia*, an herbal drug was reported to inhibit the Fenton mediated free radical formation through iron chelating properties (Singh et al., 2003).

Copper plays pathogenic role in primary biliary cirrhosis. The traces of soluble copper can catalyze the transformation of superoxide radical anion to highly reactive hydroxyl radical. Hydroxyl radical initiate lipid peroxidation results in oxidative damage of tissues. The level of serum copper was found to be increased in ethanol intoxicated rats. This might be due to the hepatic dysfunction and impaired biliary excretion. The therapeutic treatment with herbal drug *Aegle marmelos* decreased the level of serum iron and copper level to the normal level found in control animals. The action of standard drug Silymarin in serum iron and copper level in ethanol intoxicated rat was equivalent to the *Aegle marmelos* herbal drug. The results were presented in the Figure 8.

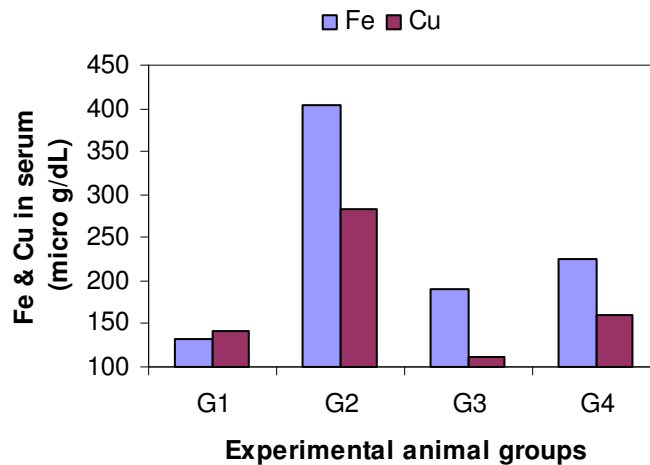


Fig 8. Effect of *Aegle marmelos* in serum Fe and Cu level

Conclusions

Our research studies data suggest that, there were significant variations in the observed biochemical parameters. The level of TBARS in ethanol intoxicated rats increased two fold when compared with the control animals. The levels of GSH, SOD and CAT decreased significantly in the ethanol intoxicated rats. The level of GPx was increased in the ethanol intoxicated rats. The value of

vitamin E in both plasma and liver samples were less when compared with the control animals. Similarly, the value of vitamin C was also showed decreased level in plasma. Serum iron and copper levels were elevated to a higher level. The therapeutic administrations of *Aegle marmelos* leaf fine powder greatly change the biochemical parameters in the ethanol intoxicated rats and maintained well to the normal level. These results

clearly suggest that, the *Aegle marmelos* have enormous hepatoprotective value. The herbal drug has equivalent therapeutic value with the standards drug Silymarin. Further, this study creates a hope on new drug discovery in controlling liver diseases

using *Aegle marmelos* as precursor. Moreover, it is very important to study the specific phytochemical compounds responsible for this hepatoprotective effect.

References

- Barker, H., Frank, O & DeAngeles, B. (1980). Plasma tocopherol in man at various times after ingestion free (or) acetylated tocopherol. *Nutr. Rep. Int.*, **21**: 531.
- Beers, R.F & Sizer, I.W. (1952). A spectrophotometric method for measuring the breakdown of hydrogen peroxide by catalase. *J. Biol. Chem.*, **195**: 133 – 140.
- Besada, A. (1987). Facile and sensitive spectrophotometric determination of ascorbic acid. *Talanta.*, **34**: 731 – 732.
- Bhattacharyay, S. (1982). Medical importance of *Aegle marmelos*. In: Chiranjib Banushadi. Ananda publisher, Kolkata, India, 341 – 346 pp.
- Comporti, M., Benedeti, A & Chieli, E. (1973). Studies on invitro peroxidation of lipids in ethanol treated rats. *Lipids.*, **8 (9)**: 498 – 502.
- Das, A.V., Padayatti, P.S & Paulose, C.S. (1996). Effect of leaf extract of *Aegle marmelos* (L) Correa ex Roxb. On histological and ultrastructural changes in tissues of streptozotocin induced diabetic rats. *Indian J. Exp. Boil.*, **34**: 341 – 345.
- Das, S., Bandyopadhyay, D., Bhattacharjee, M & Banerjee, R.K. (1997). Hydroxyl radical is the major curative factor in stress induced gastric ulceration. *Free Rad. Biol. Med.*, **23**: 8.
- Das, S., Das, S., Pal, S., Mujib, A & Dey, S. (1999). Biotechnology of medical plants – Recent advances and potential. Ist Edn, Vol – II, UK 992 Publications, Hyderabad, India, 126 – 139 pp.
- Esterbauer, H & Cheeseman, K.H. (1990). Determination of aldehydic lipid peroxidation products: Malonaldehyde and 4 – hydroxynonetal. *Meth. Enzymol.*, **186**: 407 – 421.
- Gupta, S.S. (1994). Prospects and perspectives of normal plants products in medicine. *Indian J. Pharmacol.*, **26**: 1 – 12.
- Haravey, S.K. (1968). A preliminary communication of the action of *Aegle marmelos* (Bael) on heart. *Indian J. Med. Res.*, **56**: 327 – 331.
- Henkin, R. I & Smith, F. R. (1972). Zinc and copper metabolism in acute viral hepatitis. *Am. J. Med. Sci.*, **264 (5)**: 401 – 409.
- Kakkar, P., Das, B & Viswanathan, P.N. (1984). A modified spectrophotometric assay of SOD. *Indian J. Biochem. Biophys.*, **21**: 130 – 132.
- Karunanayake, E.H., Welihinda, J., Sirimanne, S.R & Sinnadorai, G. (1984). Oral hypoglycemic activity of some medicinal plants of Sri Lanka. *J. Ethno Pharmacol.*, **11**: 223 – 231.
- Kirtikar, K.R., Basu, B.D. (1993). *Indian medicinal plants IInd Edn.* Periodical Experts Books Agency, New Delhi, 499 – 505 pp.
- Nadkarni, A.K. (2000). *Indian materia medica, IIIrd Edn.* Popular press, Mumbai, India, 45 – 49 pp.
- Noctor, G & Foyer, C.H. (1998). Ascorbate and glutathione: Keeping active oxygen under control. *Ann. Rev. Plant Physiol. Plant Molec. Biol.*, **49**: 249 – 279.
- Noroozifar, M & Khorasani – Motlagh, M. (2003). Application of potassium chromate – diphenylcarbazide in the quantitative determination of ascorbic acid by spectrophotometry. *Turk J. Chem.*, **27**: 717 – 722.
- Ohkawa, H., Ohishi, N & Yagi, K. (1979). Assay for lipid peroxides in animal tissues by thiobarbituric acid reaction. *Anal. Biochem.*, **95**: 351 – 358.
- Paglia, D & Valentine, W.N. (1967). Studies on the quantitative and qualitative characterization of Erythrocyte glutathione peroxide. *The J. Lab. Clin. Med.*, **70**: 158 – 163.
- Rajadurai, M., Padmanabhan, M & Prince, P.S.M. (2005). Effect of *Aegle marmelos* leaf extract and α -tocopherol on lipid peroxidation and antioxidants in isoproterenol induced myocardial infarction in rats. *Cardiol.*, **1**: 40 – 45.
- Rajashree, C.R., Rajmohan, T & Augusti, K.T. (1998). Antiperoxidative effect of garlic in alcohol fed rats. *Indian J. Exp. Biol.*, **36**: 60 – 64.
- Reding, P., Duchateau, J & Batille, C. (1984). Oral Zn supplementation improves hepatic encephalopathy. Results of a randomized controlled trial. *Lancet (September).*, **1**: 493 – 495.
- Sabu, M.C & Ramadasan, K. (2004). Antidiabetic activity of *Aegle marmelos* and its relationship with its antioxidant properties. *Indian J. Physiol. Pharmacol.*, **48**: 81– 88.

- Sedlak, J & Lindsay, R.H. (1968). Estimation of total, protein – bound and non – protein sulfhydryl groups in tissue with Ellman’s reagent. *Anal. Biochem.*, **25**: 192 – 205.
- Seema, P.V., Sudha, B., Padayatti, P.S., Abraham, A., Raghu, K.G & Paulose, C.S. (1996). Kinetic studies of purified malate dehydrogenase in liver of streptozotocin – diabetic rats and the effect of leaf extract of *Aegle marmelos* (L) Correa ex Roxb. *Indian J. Exp. Boil.*, **34**: 600 – 602.
- Serbinova, E.A & Packer, L. (1994). Antioxidant properties of α - tocopherol and α - tocotrienol. *Meth. Enzymol.*, **234**: 354 – 366.
- Singh, S., Pandey, S.C., Srivastava, S., Gupta, V.S., Patro, B & Ghosh, A.C. (2003). Chemistry and medicinal properties of *Tinospora cordifolia* (Guduchi). *Indian J. Pharmacol.*, **35**: 83 – 91.
- Sun, Y., Oberley, L.W & Li, Y. (1998). A simple method for clinical assay of superoxide dismutase. *Clin. Chem.*, **34**: 479 – 500.
- Sur, T.K., Pandit, S & Pramanik, T. (1999). Antispermatic activity of leaves of *Aegle marmelos*, Corr. in albino rats: A preliminary report. *Biomedicine.*, **19**: 199 – 202.
- Sur, T.K., Pandit, S., Paramanik, T & Bhattacharyya, D. (2002). Effect of *Aegle marmelos* leaf on rat sperm motility: An in vitro study. *Indian J. Pharmacol.*, **34**: 276 – 277.
- Thomas, C.E., McLean, L.R., Parker, R.A & Ohlweiler, D.F. (1992). Ascorbate and phenolic antioxidant interactions in prevention of liposomal oxidation. *Lipids.*, **27**: 543 – 550.
- Winrow, V.R., Winyard, P.G., Morris, C.J & Black, D.R. (1993). Free radical in inflammation: Secondary messengers and mediators of tissue destruction. *Br. Med. Bull.*, **49**: 506 – 517.
- Yee, H.Y & Goodwin, J.F. (1974). Simultaneous determination of copper and iron in a single aliquot of serum. *Clin. Chem.*, **20(2)**: 188 – 191.